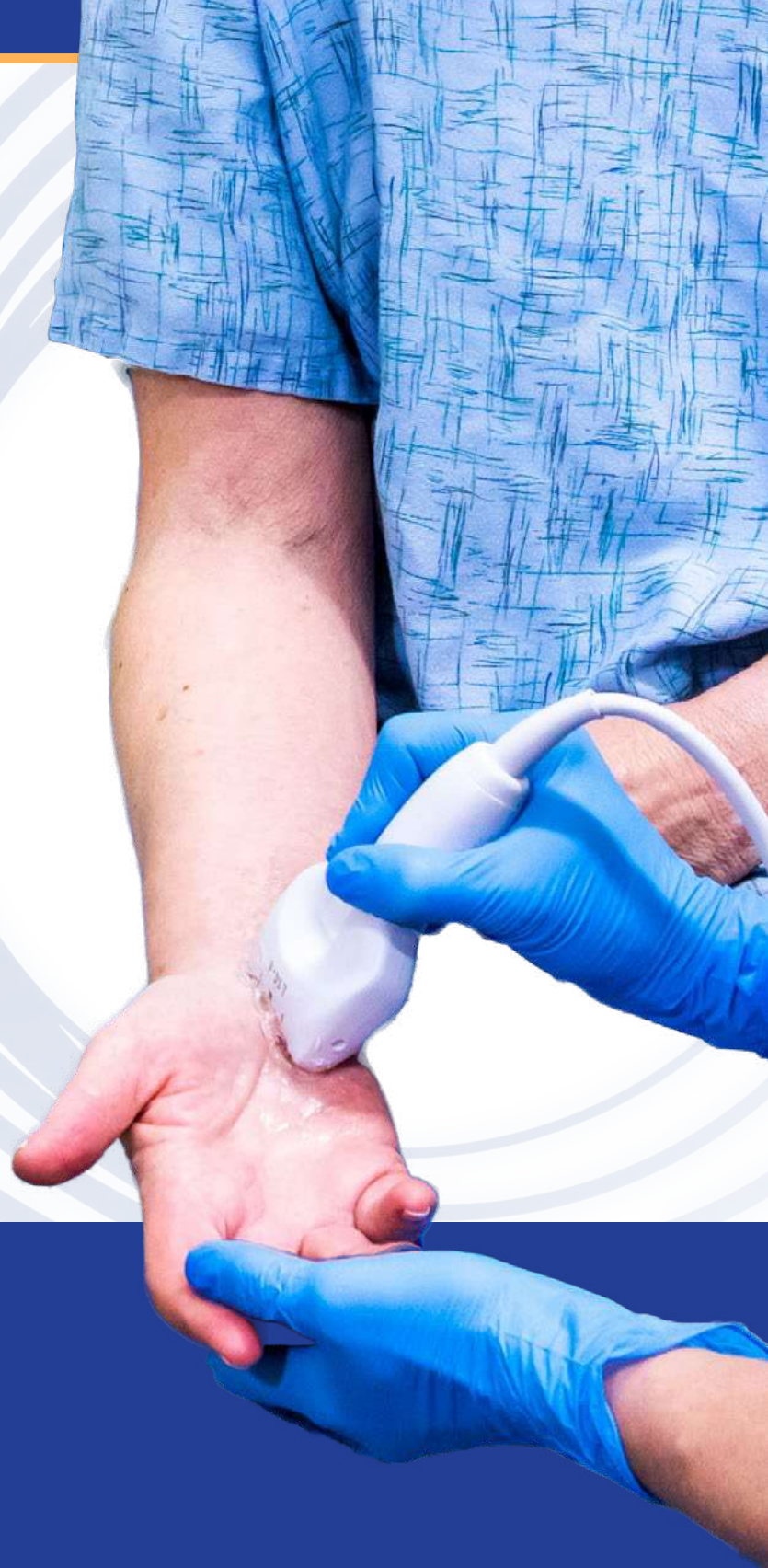



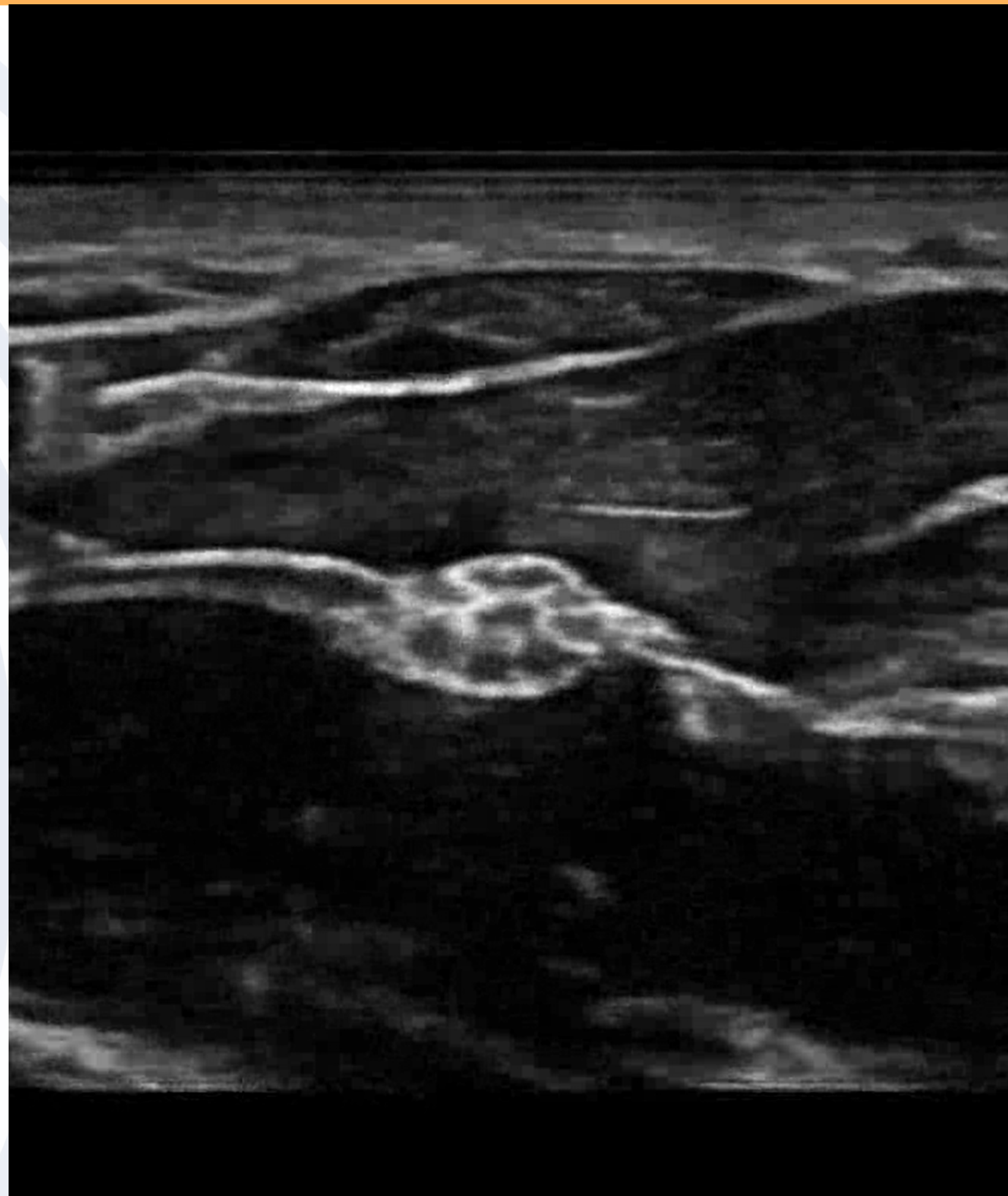
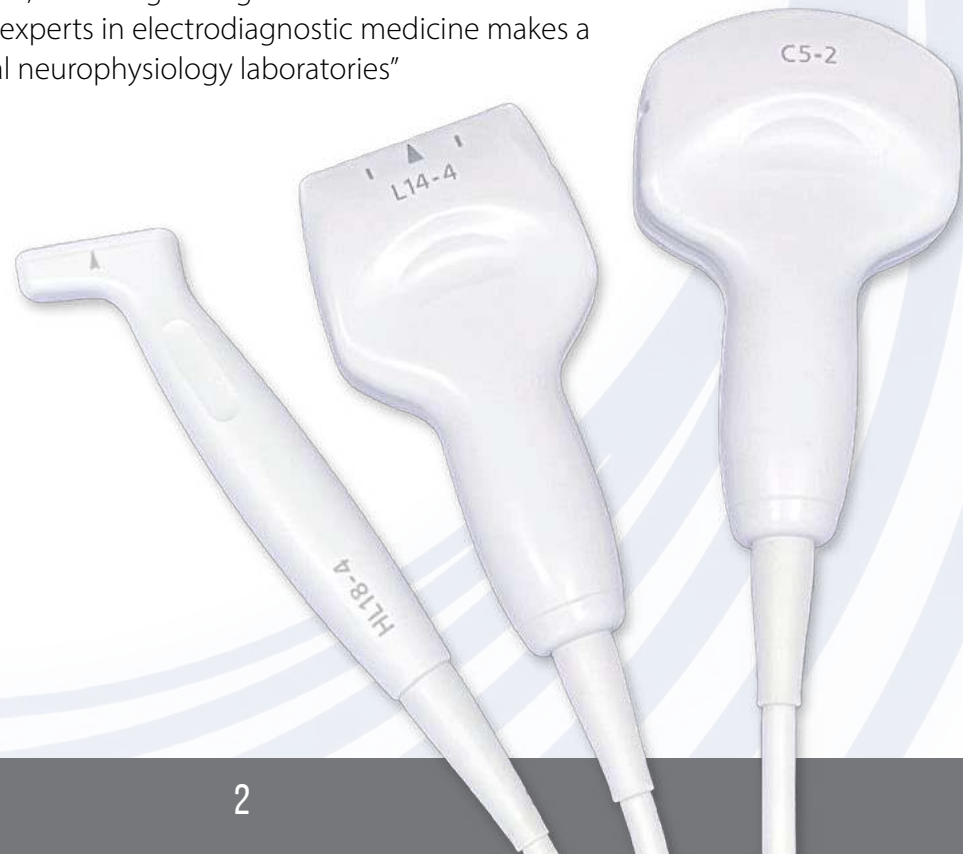CADWELL WHITEPAPER  
**THE CASE FOR  
NEUROMUSCULAR ULTRASOUND**

CADWELL WHITEPAPER

# THE CASE FOR NEUROMUSCULAR ULTRASOUND

Electromyography (EMG) and Nerve Conduction Studies (NCS) have been the standard of electrodiagnostic medicine care for the last 50 years. Recent developments in high-frequency ultrasound imaging technology have resulted in neuromuscular ultrasound (NMUS) becoming another important component of neurodiagnostic evaluations.

Francis Walker, MD, is a neurologist and professor of neurology at the Wake Forest School of Medicine Department of Neurology. His research in movement disorders has helped pioneer the development of neuromuscular ultrasound as a sophisticated, low-cost diagnostic tool (Wake Forest). "The rate of discovery of new indications for neuromuscular ultrasound," writes Francis Walker, "the endurance of previously discovered indications, the continued evolution of instrumentation, its non-invasiveness, and the growing use of ultrasound for different neuromuscular disorders by experts in electrodiagnostic medicine makes a compelling case for imaging in clinical neurophysiology laboratories" (Walker, et al., 2018).





## NEUROMUSCULAR ULTRASOUND AS A DIAGNOSTIC TOOL

Neuromuscular ultrasound can be used to investigate suspected neuromuscular disorders and diseases, including muscle weakness, fatigue, myalgia, hypotonia, and motor developmental delay (Pillen et al., 2003). Carpal tunnel syndrome is “the best understood, easiest to image, and most frequently encountered focal neuropathy,” (Walker, et al., 2018) and is a good place to start the neuromuscular ultrasound journey.

### MYOPATHIES

With ultrasound, you can visualize focal abnormalities affecting deeper layers of muscle and show muscle changes. A survey of experts (Walker, et al., 2018) shows that ultrasound or “ultrasound first” is used in more than half of cases indicating inflammatory myopathies, and even more frequently for:

- diaphragm paresis
- hypertrophic neuropathies
- suspected masses or tumors
- brachial plexopathy
- entrapment
- traumatic neuropathies
- unexplained muscle atrophy
- motor neuron disease
- chronic inflammatory neuropathies
- patients who are phobic or unable to tolerate electrodiagnostic studies

## NEUROPATHIES

Ultrasound can confirm the precise location of a traumatic nerve injury and assess nerve continuity. In patients with normal or abnormal electrophysiological studies, NMUS can help detect:

- Subtle structural anomalies, including nerve entrapment, tumors, cysts, accessory muscles, and anatomic landmarks and other nerve pathology (Yoon et al., 2010).
- Anatomical changes including altered dimensions like nerve enlargement and loss of internal fascicular architecture, reduction in nerve echogenicity, and vascularity (Cartwright & Walker, 2013).

### IDENTIFY UNEXPECTED FINDINGS

Neuromuscular ultrasound lends visibility to:

- **Unexpected anatomic** lesions, cysts, lipomas, tumors, or foreign bodies that may be “electrodiagnostically indistinguishable from common entrapment” (Walker, et al., 2018).
- **Injuries**, including nerve stretch, compression from hematoma, transection, projectile penetration, or muscle tear (Zywiell et al., 2011).
- **Nerve injury symptoms** that manifest at another site, and “Undesired positioning of the nerve, excessive mobility or subluxation, kinking, persistent focal notching and post-surgical scarring” (Gruber et al., 2015).
- **Normal results.** “Patients anxious to find the cause of their symptoms, particularly if electrodiagnostic studies are negative, are often reassured by ultrasound, even if it too yields negative results” (Walker, et al., 2018).

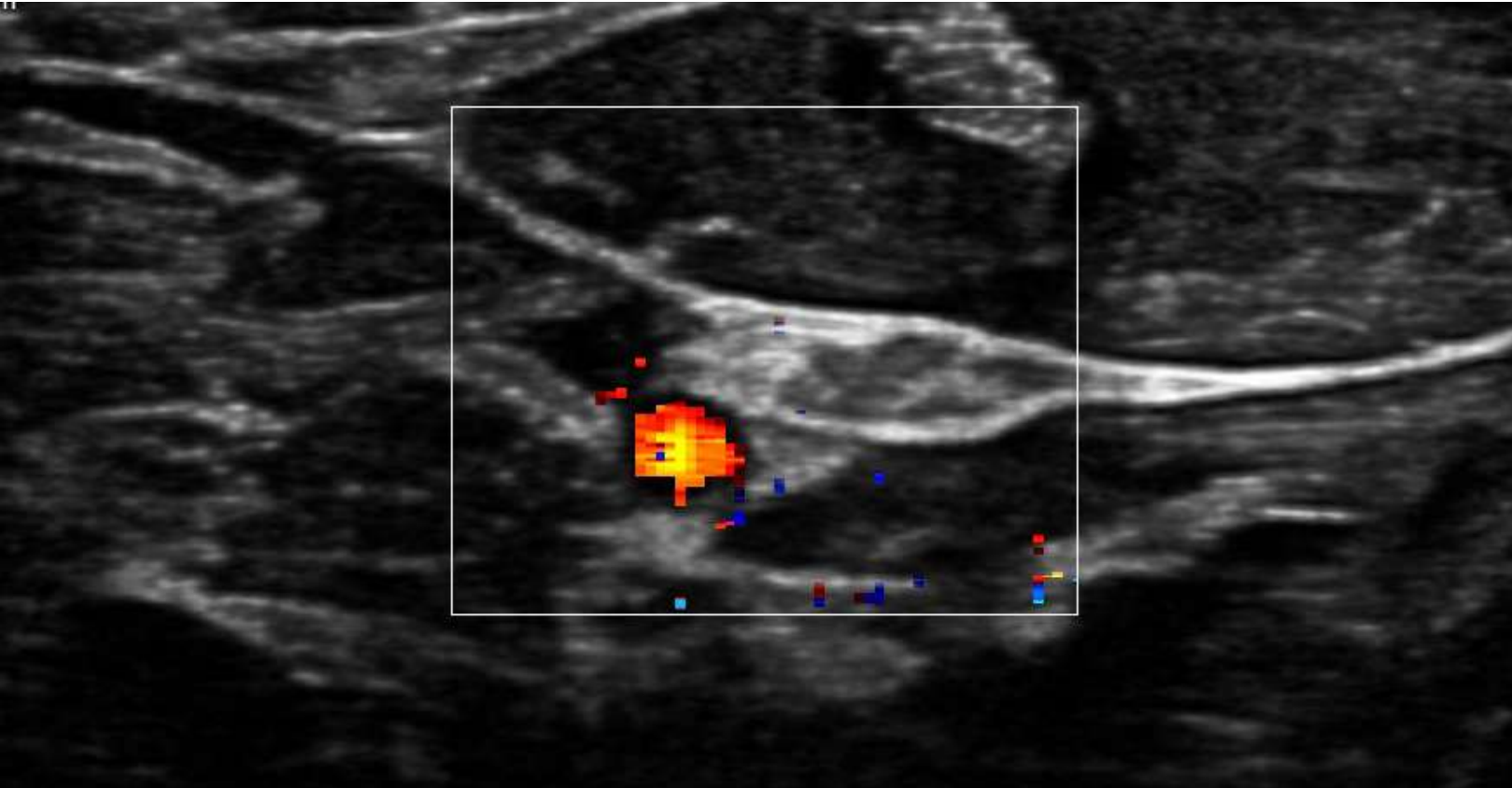


## NEUROMUSCULAR ULTRASOUND COMPLEMENTS ELECTRODIAGNOSTIC RESULTS

Ultrasound can help diagnose common entrapment neuropathies and localize other nerve problems. Combined with EMG or NCS, NMUS can increase your diagnostic certainty quickly, safely, and without discomfort.

### WITH ULTRASOUND, YOU CAN:

- **Provide important information** when electrical responses are absent, when natural or surgical anatomical variations are present, when inching is not possible, and when neuromuscular dysfunction is not severe enough to be detected electrically.
- **Provide additional evidence** of focal neuropathies or myopathies independent of electrophysiological findings, especially when electrodiagnostic studies are borderline, non-localizing, unusual, or even normal in symptomatic patients (Gans & Van Alfen, 2017).
- **Enhance NCS** when short segment NCS are not always possible (Deimel et al., 2013).
- **Test muscles that cannot be easily accessed** with EMG, and in uncooperative patients, such as children and critical care patients.
- **Increase diagnostic certainty.** Comprehensively and efficiently screen, evaluate, and facilitate the treatment of patients with suspected neurological disorders (Mah, 2018).
- **Establish structural baselines** that can be used for restudy if treatment fails (Walker, et al., 2018), or when variants are identified that can complicate NCS interpretation (Gans & Van Alfen, 2017).
- **Guide needle placement** in normal and electrically silent atrophic muscles, muscles that are difficult to reach or are in close proximity to vital organs such as the diaphragm (Boon et al., 2014) and in “Patients with poorly palpable landmarks related to obesity, prior spinal surgery, and other difficult clinical circumstances” (Soni et al., 2016).



- **Impact surgical intervention.** Ultrasound can bridge the gap between establishing a diagnosis and identifying patients likely to respond to surgical intervention (Ferrante, 2017). Neuromuscular ultrasound can help:
  - Identify patients who require future (Hanna, 2017) or urgent (Walker, et al., 2018) surgical evaluation.
  - Predict surgical intervention results (Beekman et al., 2004).
  - Pre-operatively localize nerves, guide diagnostic or preoperative anesthetic blocks, or even avoid the need for surgical exploration of suspected entrapment (Hanna, 2017).
  - Reduce the risks and expense of intervention (Walker, et al., 2018).
- **Differentiate between clinically similar diseases;** muscle involvement and chronicity in neuropathies; and affected and unaffected fascicles (Winter et al., 2017) and fasciculation detection in motor neurons, especially in the diagnosis and evaluation of ALS (Grimm et al., 2015).
- **Detect critical illness early,** thus improving standards of care (Hobson-Webb et al., 2018).

## ADVANTAGES OF ULTRASOUND

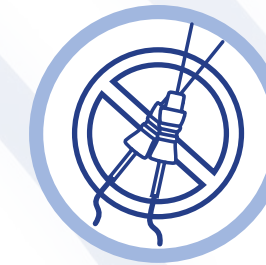Ultrasound in conjunction with electrodiagnosis can help confirm the presence of disease, determine treatment plans, and assist with biopsy guidance (Walker, et al., 2018). Early diagnosis with ultrasound is especially relevant in ALS, MS, and other neuromuscular diseases (Mah, 2018).

From early detection to critically ill patients, NMUS is a safe, non-invasive, and comfortable screening tool. Ultrasound is more affordable than CT, more comfortable than MRI, eliminates the risk of radiation, and is safe to use with metal implants. Ultrasound eliminates the risks of sedation in children or claustrophobic patients, and is such a patient-friendly screening tool that it “may be sufficient for diagnosis in some disorders or suitably informative to obviate the need for EMG or nerve conduction studies [...] and] may also help in determining if there is a need for other types of testing” (Walker, et al., 2018).



### Screen patients safely and painlessly

Ultrasound is better tolerated than needle EMG, especially in children, needle-phobic, pain-intolerant (Hellmann et al., 2005) and critically ill patients (Latronico & Bolton, 2011).



### Reduce needle sticks

Screen with NMUS before subjecting patients to more invasive techniques such as EMG, muscle biopsy, radiation, or sedation. Use NMUS to narrow down differential diagnoses, identify promising muscles for EMG sampling, reduce the number of muscles that need to be tested (Caress, 2017) and reduce the number of needle placements during EMG.



### Save time with concurrent testing

Accurate diagnosis soon after onset often leads to a more effective management strategy.



### Build trust

“Sometimes, after performing an ultrasound, enough trust is built with the examiner to allow for limited additional electrodiagnostic studies” (Walker, et al., 2018).



### Reassure patients of normal results

“It can demonstrate to the patient that nothing is apparent by ultrasound which can be quite reassuring” (Walker, et al., 2018).



### Help define anatomy

Ultrasound can be used to guide EMG and NCS studies for nerves or muscles in unusual locations, to evaluate pathology secondary to the variant anatomy (Walker, et al., 2018), and to help guide interventions around vital structures.



### Provide real-time visualization

of neuromuscular blood flow, fascicular and vascular anatomy and mobility (Park et al., 2018), and the surgical removal of nerve tumors (Simon et al., 2014).

## OTHER APPLICATIONS OF ULTRASOUND

### NEEDLE GUIDANCE

“Ultrasound is a proven tool for guiding local anesthetic injections and soft tissue biopsies, so it is not surprising that ultrasound is also effective for guiding botulinum toxin injections” (Walker, et al., 2018). Ultrasound-guided injections help improve clinical outcomes, enhance patient safety, and save procedural time. Ultrasound use with needles is correlated with patient-reported improvement in pain scores (Lee, 2017).

### BIOPSIES

Ultrasound helps determine optimal muscle biopsy site, helps avoid vessels and nerves using Doppler evaluation before and after a biopsy, minimizes complications, and offers comparable tissue sample results with less invasion than open biopsy (O’Sullivan et al., 2006). Ultrasound-guided needle EMG helps distinguish proximal muscles (Wininger et al., 2015).

---

## CONCLUSION

Clinical neurophysiologists will need to train in NMUS and acquire a device to develop skills in its use. Mastery of all applications is not necessary. Walker recommends that you master “one indication along with one nerve segment and relevant muscles. Once this is done, the technique can gradually spread to more nerve segments, muscles, indications, and members in a laboratory.” The experts he surveyed “mastered one nerve, one muscle, and one indication at a time, and now, there are ample courses and literature to guide newcomers to acquire expertise relatively quickly [...] For those readers who practice electrodiagnosis and who wish to form an independent opinion on the usefulness of neuromuscular ultrasound, we suggest that they borrow an instrument and simply look for themselves” (Walker, et al., 2018).



## REFERENCES

- Beekman, R., Wokke, J., Schoemaker, M., Lee, M., & Visser, L. (2004). Ulnar neuropathy at the elbow: follow-up and prognostic factors determining outcome. *Neurology*, 1675-1680.
- Boon, A., Sekiguchi, H., Harper, C., Strommen, J., Ghahfarohki, L., & Watson, J. (2014). Sensitivity and specificity of diagnostic ultrasound in the diagnosis of phrenic neuropathy. *Neurology*, 1264-1270.
- Caress, J. (2017). Optimal muscle selection in amyotrophic lateral sclerosis and the end of the 4-limb EMG. *Muscle Nerve*, 56:4-6.
- Cartwright, M., & Walker, F. (2013). Neuromuscular ultrasound in common entrapment neuropathies. *Muscle Nerve*, 696-704.
- Deimel, G., Jelsing, E., & Hall, M. (2013). Musculoskeletal Ultrasound in Physical Medicine and Rehabilitation. *Current Physical Medicine and Rehabilitation Reports*, 38-47.
- Ferrante MA, F. N. (2017). The thoracic outlet syndromes: Part 1. Overview of the thoracic outlet syndromes and review of true neurogenic thoracic outlet syndrome. *Muscle Nerve*, 782-793.
- Gans, P., & Van Alfen, N. (2017). Nerve ultrasound showing Martin-Gruber anastomosis. *Muscle Nerve*, 46-7.
- Grimm, A., Prell, T., Decard, B., Schumacher, U., Witte, O., & Axer, H. (2015). Muscle ultrasonography as an additional diagnostic tool for the diagnosis of amyotrophic lateral sclerosis. *Clinical Neurophysiology*, 820-827.
- Gruber, H., Baur, E., Plaikner, M., & Loizides, A. (2015). The ulnar nerve after surgical transposition: can sonography define the reason of persisting neuropathy? *Rofo*, 998-1002.
- Hanna AS, E. M. (2017). Preoperative ultrasound-guided wire localization of the lateral femoral cutaneous nerve. *Oper Neurosurg*, 402-408.
- Hellmann, M., von Kleist-Retzow, J., Haupt, W., Herkenrath, P., & Schauseil-Zipf, U. (2005). Diagnostic value of electromyography in children and adolescents. *Journal of Clinical Neurophysiology*, 43-48.
- Hobson-Webb, L., Preston, D., & Cartwright, M. (2018). Neuromuscular ultrasound: a call for training and education. *Muscle Nerve*, 168-169.
- Latronico, N., & Bolton, C. (2011). Critical illness polyneuropathy and myopathy: a major cause of muscle weakness and paralysis. *Lancet Neurology*, 931-94.
- Lee, Y. C. (2017). Ultrasonographic changes after steroid injection in carpal tunnel syndrome. *Skeletal Radiology*, 46(11):1521-1530.
- Mah, J. a. (2018). Neuromuscular Ultrasound: Clinical Applications and Diagnostic Values. *The Canadian Journal of Neurological Sciences*, 605-619.
- O’Sullivan, P., Gorman, G., Hardiman, O., Farrell, M., & Logan, P. (2006). Sonographically guided percutaneous muscle biopsy in diagnosis of neuromuscular disease. *Journal of Ultrasound Medicine*, 1-6.
- Park, G., Kwon, D., Seok, J., Park, D., & Cho, H. (2018). Usefulness of ultrasound assessment of median nerve mobility in carpal tunnel syndrome. *Acta Radiol*.
- Pillen, S., Scholten, R., Zwartz, M., & Verrips, A. (2003). Quantitative skeletal muscle ultrasonography in children with suspected neuromuscular disease. *Muscle Nerve*, 699-705.
- Santamato, A., Micello, M., & F, P. (2014). Can botulinum toxin type A injection technique influence the clinical outcome of patients with post-stroke upper limb spasticity? A randomized controlled trial comparing manual needle placement and ultrasound-guided injection techniques. *Journal of Neurological Science*, 39-43.
- Simon, N., Cage, T., Narvid, J., Noss, R., Chin, C., & Kliot, M. (2014). High-resolution ultrasonography and diffusion tensor tractography map normal nerve fascicles in relation to schwannoma tissue prior to resection. *Journal of Neurosurgery*, 1113-1117.
- Soni, N., Franco-Sadud, R., & Schnobrich, D. (2016). Ultrasound guidance for lumbar puncture. *Neurol Clin Pract*, 358-368.
- Wake Forest Innovations. <https://www.wakeforestinnovations.com/experts/francis-walker/>.
- Walker, F., Cartwright, M., Alter, K., Visser, L., et al. (2018). Indications for neuromuscular ultrasound: Expert opinion and review of the literature. *Clinical Neurophysiology*, 2658-2679.
- Wininger, Y., Buckalew, N., Kaufman, R., & Munin, M. (2015). Ultrasound combined with electrodiagnosis improves lesion localization and outcome in posterior interosseous neuropathy. *Muscle Nerve*, 1117-1121.
- Winter, N., Rattay, T., Axer, H., Schaffer, E., Decard, B., & Gugel, I. (2017). Ultrasound assessment of peripheral nerve pathology in neurofibromatosis type 1 and 2. *Clinical Neurophysiology*, 702-706.
- Yoon, J., Walker, F., & Cartwright, M. (2010). Ulnar neuropathy with normal electrodiagnosis and abnormal nerve ultrasound. *The Archives of Physical Medicine and Rehabilitation*, 318-320.
- Zywiell, M., Mont, M., McGrath, M., Ulrich, S., Bonutti, P., & Bhave, A. (2011). Peroneal nerve dysfunction after total knee arthroplasty: characterization and treatment. *Journal of Arthroplasty*, 379-386.



Contact us at: [info@cadwell.com](mailto:info@cadwell.com)

[www.cadwell.com](http://www.cadwell.com) | [cadwell.support](mailto:cadwell.support) | [cadwell.education](http://cadwell.education) | [www.estore.cadwell.com](http://www.estore.cadwell.com)

Cadwell Industries, Inc.

909 N. Kellogg St. Kennewick, WA 99336

+1 (800) 245-3001 | +1 (509) 735-6481 | +1 (844) 364-1283 fax

© 2022 Cadwell Industries, Inc. All rights reserved. 20220819

The information contained in this document is subject to change without notice. This document contains trademarks that belong to Cadwell Industries, Inc. and other companies, respectively.